



Effects of inhibition of prostaglandin endoperoxide synthase-2 in chronic gastro-intestinal ulcer models in rats

²Adrian Schmassmann, ¹Brigitta M. Peskar, Christian Stettler, Peter Netzer, ¹Thomas Stroff, Beatrice Flogerzi & Fred Halter

Department of Medicine, Gastrointestinal Unit, University of Bern, Inselspital, 3010 Bern, Switzerland and ¹Department of Experimental Clinical Medicine, Ruhr-University, Building MA, Universitätsstrasse 150, D-44787 Bochum, Germany

1 In the stomach, prostaglandins protect the gastric mucosa against injuries. One rate-limiting step in prostaglandin synthesis is mediated by prostaglandin endoperoxide synthase (PGHS), the target enzyme of non-steroidal anti-inflammatory drugs (NSAIDs). Two isoforms of PGHS exist: a constitutive (PGHS-1) and an inducible (PGHS-2) enzyme. PGHS-1 is the major source of gastric prostaglandins under physiological conditions. Inhibition of prostaglandin synthesis by traditional NSAIDs such as indomethacin and diclofenac which non-selectively inhibit both PGHS-1 and PGHS-2, causes gastric and intestinal ulceration and delays gastric ulcer healing in chronic models. It has been shown that selective PGHS-2 inhibitors such as L-745,337 (5-methanesulphonamido-6-(2,4-difluorothiophenyl)-1-indanone) are not ulcerogenic and do not inhibit gastro-intestinal prostaglandin synthesis. However, minimal information is available on the long-term effects of PGHS-2 inhibitors on the healing of previously established gastric injuries. We assessed the cellular localization and expression of PGHS-1 and PGHS-2 during gastric ulcer healing and assessed the effects of L-745,337 on previously established cryoulcers in the rat gastric stomach.

2 PGHS-1 and PGHS-2 were located and quantified by immunohistochemistry during experimental gastric ulcer healing. PGHS-2 immunoreactivity was only negligible in the normal gastric wall, but after gastric ulcerations, it was strongly detected in monocytes, macrophages, fibroblasts and endothelial cells below and between the regenerative glands. PGHS-1 immunoreactivity detected in normal gastric mucosa, disappeared after gastric ulceration in the mucosa adjacent to the ulcer crater. However, it reappeared in the regenerative glands from day 5 onwards. Thus, PGHS-1 and PGHS-2 were located at different sites and their maximal expression followed a different time-sequence.

3 We assessed the effects of L-745,337, indomethacin and diclofenac on gastric ulcer healing and histological healing parameters in rats. L-745,337, indomethacin and diclofenac dose-dependently decreased the healing of gastric ulcers. L-745,337, indomethacin and diclofenac decreased epithelial cell proliferation in the ulcer margin and microvessel density in the ulcer bed on day 8 and increased the thickness of the granulation tissue below the ulcer crater and the gap between both edges of the muscularis mucosae on day 15. Indomethacin and diclofenac, but not L-745,337, decreased synthesis of 6-keto-PGF_{1α} and PGE₂ in tissue fragments from the stomach and terminal ileum and decreased platelet thromboxane B₂ synthesis in clotting whole blood.

4 Dose-response curves for the inhibition of chronic gastric ulcer healing by L-745,337 (administered twice daily intragastrically) showed an ID₅₀ value of 1.7 mg (4.3 μmol) kg⁻¹. Dose-response curves for the inhibition of PGE₂ synthesis in inflammatory exudates in the acute carrageenin sponge rat model, showed ID₅₀ values of 1.1 mg (3.1 μmol) kg⁻¹ and 1.3 (3.3 μmol) mg kg⁻¹ for indomethacin and L-745,337, respectively. Thus, inhibition of chronic gastric ulcer healing by L-745,337 occurs within a potentially therapeutic dose-range.

5 In summary, PGHS-2 is markedly accumulated after gastric ulceration in monocytes, macrophages, fibroblasts and endothelial cells in regions of maximal repair activity. Selective inhibition of PGHS-2 by L-745,337 delayed gastric ulcer healing though interference with epithelial cell proliferation, angiogenesis and maturation of granulation tissue in a potentially therapeutic dose range. PGHS-2-derived prostaglandins seem to have an important role in gastric ulcer healing.

Keywords: Non-steroidal anti-inflammatory drugs; cyclo-oxygenase-2; prostaglandin endoperoxide synthase; indomethacin; L-745,337 (5-methanesulphonamido-6-(2,4-difluorothiophenyl)-1-indanone); immunoreactivity; cellular localization; gastric ulcer healing; anti-inflammatory action

Introduction

In the stomach, prostaglandins stimulate the secretion of mucus and bicarbonate and protect the gastric mucosa against injuries (Robert *et al.*, 1979; Wallace, 1997). One rate-limiting step in eicosanoid biosynthesis is the conversion of arachidonic acid to prostaglandins by prostaglandin endoperoxide

synthase (PGHS), which is the target enzyme of non-steroidal anti-inflammatory drugs (NSAIDs) (Vane, 1971). Two isoforms of PGHS exist: a constitutive (PGHS-1) and an inducible (PGHS-2) enzyme (Xie *et al.*, 1991; Vane 1994). Under physiological conditions, PGHS-1 participates in the production of tissue prostaglandins and has been localized to the apical cytoplasm of mucous neck cells of the gastric glands (Iseki, 1995). PGHS-2 expression in the normal stomach is

² Author for correspondence.

controversial, but investigators agree that much less PGHS-2 is expressed than PGHS-1 (O'Neill & Ford-Hutchinson, 1993; Kargman *et al.*, 1996; Ferraz *et al.*, 1997). It has been suggested that the anti-inflammatory action of NSAIDs is due to the inhibition of PGHS-2, whereas the gastro-intestinal side-effects are due to inhibition of PGHS-1 (Vane, 1994a).

Therefore, several PGHS-2 inhibitors have been developed including L-745,337, L-748,731, NS-398, SC 58635, DuP 697 and meloxicam (Donnelly & Hawkey, 1997). They do not inhibit gastric prostaglandin synthesis and cause no visible gastro-intestinal lesions in acute studies at doses with adequate anti-inflammatory action (Chan *et al.*, 1995; Panara *et al.*, 1995). L-745,337 (5-methane-sulphonamido-6-(2,4-difluorothiophenyl)-1-indanone) is a highly selective inhibitor of PGHS-2 (PGHS-2/PGHS-1 selectivity *in vitro* <0.0005) with well-characterized pharmacokinetic properties (Li *et al.*, 1995; Donnelly & Hawkey, 1997).

Traditional NSAIDs such as indomethacin and diclofenac, nonselectively inhibit both PGHS-1 and PGHS-2 and delay gastric ulcer healing (Schmassmann *et al.*, 1995; Wallace, 1997). They interfere with epithelial cell proliferation in the ulcer margin, angiogenesis in the ulcer bed and maturation and contraction of granulation tissue below the ulcer crater (Levi *et al.*, 1990; Schmassmann *et al.*, 1995). This interference increases the thickness of the granulation tissue and the gap between both edges of the muscularis mucosae (Ogihara & Okabe, 1993; Schmassmann *et al.*, 1995).

PGHS-2 mRNA and protein are markedly increased at inflammation and repair sites in several animal and human tissues including gastrointestinal tissue (Reuter *et al.*, 1996; Mizuno *et al.*, 1997). PGHS-2 is expressed in fibroblasts after stimulation of growth factor (Reddy *et al.*, 1994), in macrophages after stimulation by lipopolysaccharides and interleukin 1 (Lee *et al.*, 1992) and in endothelial cells after stimulation by platelet microparticles (Barry *et al.*, 1997). So far, there has been little information on the effects of PGHS-2 inhibitors on preexisting gastrointestinal lesions. Two recent studies (Reuter *et al.*, 1996; Mizuno *et al.*, 1997) showed that selective inhibition of PGHS-2 decreased PGHS-2-mediated prostaglandin synthesis and impaired experimental ulcer healing in the mouse and caused exacerbation of experimental colitis in the rat. These results suggest a role for PGHS-2-derived prostaglandins in inflamed or ulcerated gastro-intestinal tissue. However, relevant information on the role of PGHS-1- and PGHS-2-derived prostaglandins in the gastrointestinal tract repair process is lacking. Therefore, in the first part of this study, we determined the cellular localization and time-sequence of PGHS-1 and PGHS-2 during gastric ulceration. In the second part of the study, we assessed the dose-dependent effects of indomethacin, diclofenac and L-745,337 on the gastric ulcer healing process and on prostanoid synthesis in the stomach, ileum and platelets. To assess whether L-745,337 induced interference with gastric ulcer healing processes at relevant doses, we further assessed the anti-inflammatory action of various doses of indomethacin and L-745,337 in an acute carrageenin-induced inflammation model in rats.

Preliminary studies

All studies were approved by the Animal Study Committee of the University of Bern, Switzerland. The preliminary studies assessed the optimal doses and drug administration routes (s.c. or intragastrically: i.g.). Ninety-six female Wistar rats (6 rats per group) with cryoulcers and fitted with a gastric cannula (see below and Schmassmann *et al.*, 1995) were treated twice

daily with various doses of indomethacin (0.1, 0.5, 0.75 and 1 mg kg⁻¹, s.c. and 0.1, 0.5, 0.75 and 1 mg kg⁻¹, i.g.), diclofenac (0.25, 1, 2.5 and 5 mg kg⁻¹, i.g.) and L-745,337 (0.25, 1, 2, 5 mg kg⁻¹, i.g.).

No significant effects on ulcer healing were observed in rats treated twice daily with: indomethacin 0.1 mg kg⁻¹, s.c. and i.g., diclofenac 0.25 mg kg⁻¹, i.g. and L-745,337 0.25 mg kg⁻¹, i.g. The bowel perforation rate was 0% for indomethacin 0.1 and 0.5 mg kg⁻¹, s.c., indomethacin 0.1 mg kg⁻¹, i.g., diclofenac 0.25–1 mg kg⁻¹, i.g. and L-745,337 0.5–2 mg kg⁻¹, i.g.; 33% for diclofenac 2.5 mg kg⁻¹, i.g. and L-745,337 5 mg kg⁻¹, i.g., 50% for indomethacin 0.75 mg kg⁻¹, s.c.; 67% for indomethacin 0.5 mg kg⁻¹, i.g. and 100% for indomethacin 1 mg kg⁻¹, s.c., indomethacin 0.75 mg kg⁻¹, i.g., indomethacin 1 mg kg⁻¹, i.g. and diclofenac 5 mg kg⁻¹, i.g. Based on these preliminary data, we used indomethacin 0.1 and 0.5 mg kg⁻¹, s.c., diclofenac 0.25, 1 and 2.5 mg kg⁻¹, i.g., and L-745,337 0.5, 2, and 5 mg kg⁻¹, i.g. in the principal study. Diclofenac and L-745,337 were given i.g. because this is the preferred therapeutic route. Indomethacin was not administered i.g. because of the high intestinal perforation rate at doses which significantly delay gastric ulcer healing.

PGHS-1 and PGHS-2 immunoreactivity during gastric ulcer healing

Rats with cryoulcers (4 rats per time-point) were killed 1, 2, 3, 5, 6, 8, 10, 15 and 21 days after ulcer induction. Six rats without ulcers were used to assess immunoreactivity in the normal gastric wall. A single i.p. injection of 100 mg kg⁻¹ bromodeoxyuridine (BrdU) was administered 1 h before the stomach was removed.

Ulcer induction After feeding, the rats were anaesthetized with ether and the abdomen opened by medical incision. A cryo-injury was made on the serosal surface of the midcorpus (Schmassmann *et al.*, 1995). Briefly, a cryoprobe (diameter: 6.5 mm) cooled to –60°C by gaseous CO₂ was applied to the gastric wall for 45 s. The abdomen was closed and the rats kept under normal laboratory conditions with free access to water and a standard pelleted rat diet (Naphag, Gossau, Switzerland).

PGHS-1 and PGHS-2 immunoreactivity To decrease non-specific staining, deparaffinized sections (5 µm) were treated with 3% hydrogen peroxide for 5 min and, after washing, incubated in 20% normal goat serum for 20 min. The sections were then incubated in TBS with primary antibodies for PGHS-1 and PGHS-2 alone (1:400), or after an overnight, at room temperature, preincubation with 100–2000 ng ml⁻¹ of the corresponding peptide as a preabsorption control. After being washed (TBS, 3 × 10 min), the sections were incubated with biotinylated goat-anti-rabbit immuno-globulin G (1:200) for 1 h at room temperature, washed with TBS and incubated for further 45 min with streptavidin-conjugated horseradish peroxidase. After being washed, the sections were incubated for 7 min with biotinylated tyramine (1:50) to amplify the signal, washed and then incubated with streptavidin-conjugated horseradish peroxidase (1:500) for 30 min. Aminoethyl carbazole was used as a chromogen. The slides were slightly counterstained with Mayer's haematoxylin.

The number of cells expressing PGHS-1 was measured in a 600 µm wide region of normal mucosa and in a 600 µm wide region of the mucosal ulcer margin adjacent to the ulcer crater. The results are expressed as a percentage of the total number

of epithelial cell nuclei. The number of cells expressing PGHS-2 was measured in a 600 μm wide and 300 μm deep region of granulation tissue below the regenerative glands adjacent to the ulcer crater. The results are expressed as a percentage of the total number of non-epithelial cell nuclei. The mean value per rat was determined by examining 10 sections.

BrdU immunoreactivity Epithelial cell proliferation was assessed by immunohistochemical detection of DNA synthetic phase cells with antibodies against BrdU (Schmassmann *et al.*, 1994; 1995). The percentage of BrdU-labelled epithelial cells in a 600 μm wide region of the mucosa adjacent to the ulcer crater was determined in rats treated for 8 days. Ten sections per rat were evaluated to calculate the mean.

Effects of drugs on gastric ulcer healing

Study groups A gastric cannula (steel, inner diameter: 8 mm) allowing video endoscopic examination of the gastric mucosa, was placed into the rumen of female Wistar rats (body weight: 180–200 g). Three weeks later, standardized gastric ulcers were produced by a cryoprobe as described above (Schmassmann *et al.*, 1995). Rats without standardized (round ulcers with an ulcer diameter of 3–5 mm) ulcers at the first video endoscopy were excluded from the trial. One day after cryo-injury, 178 rats were randomly assigned to one of thirteen treatment groups. Rats received twice daily doses of the following: (1) placebo (sterile normal saline) s.c. for 8 days (8 rats) and 15 days (24 rats); (2) placebo, i.g. (8 rats); (3) omeprazole 20 $\mu\text{mol kg}^{-1}$, s.c. (8 rats); (4) indomethacin 0.1 mg (0.28 $\mu\text{mol kg}^{-1}$, s.c. (6 rats); (5) indomethacin 0.5 mg (1.4 $\mu\text{mol kg}^{-1}$, s.c. for 8 days (8 rats) and 15 days (16 rats); (6) indomethacin 0.5 mg (1.4 $\mu\text{mol kg}^{-1}$, s.c. + 20 $\mu\text{mol kg}^{-1}$ omeprazole, s.c. (8 rats); (7) diclofenac 0.25 mg (0.78 $\mu\text{mol kg}^{-1}$, i.g. (6 rats); (8) diclofenac 1 mg (3.14 $\mu\text{mol kg}^{-1}$, i.g. (12 rats); (9) diclofenac 2.5 mg (7.85 $\mu\text{mol kg}^{-1}$, i.g. for 8 days (8 rats) and 15 days (16 rats); (10) L-745,337 0.5 mg (1.28 $\mu\text{mol kg}^{-1}$, i.g. (6 rats), (11) L-745,337 2 mg (5.12 $\mu\text{mol kg}^{-1}$, i.g. (12 rats); (12) L-745,337 5 mg (12.8 $\mu\text{mol kg}^{-1}$, i.g. for 8 days (8 rats) and 15 days (16 rats), and (13) L-745,337 2 mg (5.12 $\mu\text{mol kg}^{-1}$, i.g. + 20 $\mu\text{mol kg}^{-1}$ omeprazole, s.c. (8 rats). The drugs were given at 08 h 00 min and 16 h 00 min. Groups 1, 5, 9 and 12 were treated for 8 and 15 days and the others for 15 days. Rats were killed 1 h after the last dosing which was combined with a single i.p. injection of 100 mg kg^{-1} BrdU.

Video endoscopy This was performed on days 3, 8 and 15, without fasting (Schmassmann *et al.*, 1995). Briefly, the rats were immobilized in Bollman cages without anaesthesia. Food present in the stomach was washed out through the gastric cannula. The endoscope, equipped with a video camera, was introduced through the cannula. To measure the ulcer size, a piece of calibration paper (diameter 4 mm) was placed close to the ulcer crater. Both the ulcer and calibration paper were recorded by the video endoscopy and the image transferred to a personal computer. The gastric lumen was fully distended by air insufflation. The ulcer diameter was calculated according to the formula: diameter = $2 \times \sqrt{(\text{area}/\pi)}$. To eliminate the influence of the initial variation in ulcer diameter, all results are expressed as a percentage of the initial ulcer size on day 3. The ulcer healing rate (ulcer size reduction per day) from days 8–15 was calculated with the formula: (D (in %) on day 8) – (D (in %) on day 15) / 7 (Schmassmann *et al.*, 1995). The rats showed no sign of discomfort during endoscopy.

Quantitative histomorphometric assessment The rats were anaesthetized with ether and a laparotomy was performed. The stomach was opened along the greater curvature and slightly stretched on a paraffin panel to prevent mucosal folding. Gastric specimens were fixed for 4 h in 4% buffered paraformaldehyde, then dehydrated gradually in ethanol, embedded in paraffin and cut into 5 μm sections. Coded gastric sections were stained with haematoxylin and eosin before light microscope evaluation (Olympus BH-2, Tokyo, Japan). Morphometric analysis was performed by use of a video camera (Ci-20 P Canon, Tokyo, Japan) and a semiautomatic image analysis system (Microvid software, Leica, Zürich, Switzerland). The following parameters were determined in ten histological sections (Schmassmann *et al.*, 1994): (1) mucosal thickness, (2) ulcer area, (3) thickness of granulation tissue in the ulcer bed at the ulcer centre and (4) gap between both edges of the muscularis mucosae measured at the ulcer centre. The number of microvessels in the ulcer bed was determined after identification by immunohistochemistry with antibodies against von Willebrand factor (factor VIII-related antigen), which is localized in the endothelial cells (Schmassmann *et al.*, 1995). The number of microvessels in the granulation tissue was counted on coded sections under a 400 \times microscopic magnification. Microvessel density was expressed as the number of microvessels mm^{-2} granulation tissue and the mean density was assessed from 10 histological sections from rats treated for 8 days.

Intestinal perforation Autopsy was performed on all rats which died during the treatment course. Special care was taken to assess ascites and to localize the site of intestinal perforation. These were excluded from morphometric analyses.

Plasma gastrin concentration Plasma gastrin measured at the start and at death as previously described (Schmassmann *et al.*, 1995).

Acute model for assessing induction of gastro-intestinal ulceration

Assessment of the gastric ulcers Thirty rats were deprived of food and treated with indomethacin (5 mg (14.0 μmol) and 20 mg (56.0 $\mu\text{mol kg}^{-1}$, i.g.), L-745,337 (5 mg (12.8 μmol) and 20 mg (51.2 $\mu\text{mol kg}^{-1}$, i.g.) or placebo (5 rats per active treatment group, 10 vehicle rats). Gastric mucosal damage was assessed 5 h after drug administration from a lesion index with a 0–3 scoring system (severity factor 1: lesions <2 mm; severity factor 2: lesions 2–4 mm, severity factor 3: lesions >4 mm) (Lambrecht *et al.*, 1993). Measurement of prostaglandin synthesis in the oxyntic mucosa is described later.

Assessment of the intestinal ulcers Fifty fed rats were treated with indomethacin (5 and 20 mg kg^{-1} , i.g.), L-745,337 (5 and 20 mg kg^{-1} , i.g.) or placebo (5 rats per active treatment group, 10 rats in vehicle group) (Beck *et al.*, 1990). Rats were killed 5 or 24 h after dosing. The small intestine was removed and opened on the side opposite the mesentery and the lesions were assessed as described above for gastric ulcers. The values are the number of lesions multiplied by the respective severity factor in the distal 10 cm of ileum. Measurement of prostaglandin synthesis in the terminal ileum (20 mg full wall) is described later.

In additional experiments, fifteen non-fasted rats were treated daily either with placebo, indomethacin (2 \times 5 mg (14.0 $\mu\text{mol kg}^{-1}$) or L-745,337 (2 \times 5 mg (12.8 $\mu\text{mol kg}^{-1}$)).

i.g. for 4 days (5 rats per group). On the morning of day 5, one hour after the last dosing, the intestine was removed and assessed as described above, and prostaglandin synthesis in the gastric mucosa and terminal ileum was assessed as described below.

Prostanoid synthesis in the gastrointestinal tract and blood

Acute and chronic ulcer models One hour after dosing, the synthesis of 6-keto-PGF_{1 α} and PGE₂ was assessed in tissue fragments of intact gastric oxyntic mucosa (20 mg, mucosa only) and terminal ileum (20 mg, total wall) as well as platelet thromboxane (TX) B₂ synthesis in clotting whole blood (incubation at 37°C for 60 min) (Lambrecht *et al.*, 1993; Panara *et al.*, 1995).

Gastric or intestinal tissues (20 mg) were incubated in 0.6 ml of oxygenated Tyrode solution at 37°C for 10 min. Release of 6-keto-PGF_{1 α} (stable metabolite of prostacyclin) and PGE₂ into the incubation medium were determined with a specific radioimmunoassay (RIA) (Lambrecht *et al.*, 1993).

Acute model for assessing anti-inflammatory action of NSAIDs

To compare gastro-intestinal toxicity and anti-inflammatory action, indomethacin (s.c.) and L-745,337 (i.g.) were administered in the inflammation model by the same route as in the chronic ulcer healing model. Sterile polyester sponges (1.3 × 0.7 × 0.4 cm) were soaked in 2% carrageenin (w/v) in saline. They were implanted s.c. into forty-three male Wistar rats. Five hours after implantation, the sponges were removed under ether anaesthesia and immersed in 2.0 ml phosphate (0.01 M, pH 7.4)-buffered saline containing 5 U ml⁻¹ heparin. They were then squeezed and the exudates centrifuged (1500 × g, 4°C, 10 min). The supernatants were analysed for their PGE₂ content with RIA. Indomethacin (0.05–5 mg kg⁻¹, 12 rats) was injected s.c., L-745,337 (0.05–5 mg kg⁻¹, 17 rats) and dexamethasone (3 mg kg⁻¹, 4 rats) were administered i.g. immediately before sponge insertion (Peskar *et al.*, 1991). Dexamethasone was administered to inhibit selectively synthesis of PGHS-2-derived prostaglandins.

Methods

Materials

The polyclonal rabbit antibodies against ovine PGHS-1 and murine PGHS-2, including their corresponding antigens, were obtained from Cayman (Ann Arbor, MI). The bromodeoxyuridine (BrdU), the primary antibodies against BrdU (mouse clone Bu20a), the rabbit anti-human von Willebrand factor and the avidin-biotin-peroxidase kit were obtained from Dako (Glostrup, Denmark). The secondary anti-mouse immunoglobulins were from Milan (La Roche, Switzerland), the normal goat serum from GIBCO (Grand Island, NY), the pepsin from Serva (Heidelberg, Germany), ABS-the Kit from Dako (Denmark) and the signal amplification kit, TSA-Indirect, from DuPont (Boston, MA). The prostanoids were obtained from Paesel and Lorei (Hanau, Germany) and the tritiated prostanoids from New England Nuclear (Dreieich, Germany). The chromogen ethyl-carbazole and all other compounds were obtained from Sigma Chemicals (St. Louis, U.S.A.).

L-745,337 was kindly provided by Merck Frosst, Quebec, Canada. Diclofenac was obtained from Sigma (Switzerland)

and omeprazole was provided by AB Hässle (Mölndal, Sweden) and dissolved in 40% polyethylene glycol. Indomethacin trihydrate (Indocid) was obtained from Merck, Sharp & Dohme (Glattbrugg, Switzerland) and diluted in deionized water.

Statistical analysis

All results are expressed as mean ± s.e.mean. Differences were tested by a one-way analysis of variance. Correlation analyses were performed according to Pearson. Probability values of $P < 0.05$ were regarded as significant (Sachs, 1973).

Results

Histology during gastric ulcer healing

Histology shows characteristic features of healing which were described in detail in our previous papers (Schmassmann *et al.*, 1994; 1995; Tarnawski & Halter, 1995). Briefly, in the early healing phase (days 0–8 after ulceration), epithelial cells as well as granulocytes, monocytes, macrophages, fibroblasts and endothelial cells adjacent to the ulcer crater constitute a region with maximal repair activity, with many cells in the DNA-synthetic phase (immunoreactive for BrdU). Gastric glands in the ulcer margin contained poorly-differentiated cells. The submucosa adjacent to the ulcer crater and the granulation tissue below the regenerative glands and the ulcer crater, were strongly infiltrated by inflammatory cells, fibroblasts and endothelial cells. In the middle phase (days 8–15), epithelial cells in the ulcer margin further proliferate and migrate over and into the ulcer crater. In the late phase (days 15–21), the ulcer crater was completely reepithelialized and replaced by the mucosal scar, which consisted of dilated glands lined with cells resembling poorly-differentiated mucous cells. Parietal and chief cells were absent in the first three weeks of healing.

Immunoreactivity of PGHS-2 and PGHS-1

PGHS-2 immunoreactivity was negligible in the normal gastric wall, but after gastric ulceration, PGHS-2 immunoreactivity was strongly detected in the cytoplasm of monocytes, macrophages, fibroblasts and endothelial cells in regions of maximal repair activity below (days 3–15) and between (day 22) the regenerative glands (Figures 1 and 2). PGHS-1 immunoreactivity was detected in 13 ± 2% of all epithelial cells and localized to the apical cytoplasm of mucous neck cells. PGHS-1 immunoreactivity disappeared after gastric ulceration in the mucosa adjacent to the ulcer crater, but it reappeared from day 5 onwards in the apical cytoplasm of the regenerative epithelial cells (Figure 1). The time-sequence of immunoreactivity for BrdU in epithelial cells and PGHS-2 in non-epithelial cells revealed a close association between BrdU and PGHS-2 (Figure 2).

Chronic model of gastric ulcer healing and intestinal perforation

There were no postoperative complications in rats treated with placebo, omeprazole or the lowest dose of NSAIDs, and the rats had the same weight gain in all groups (252 ± 3 g at start and 265 ± 2 g at death). Some rats treated with higher doses of NSAIDs developed intestinal perforation, as described later, and the data from these rats were excluded.

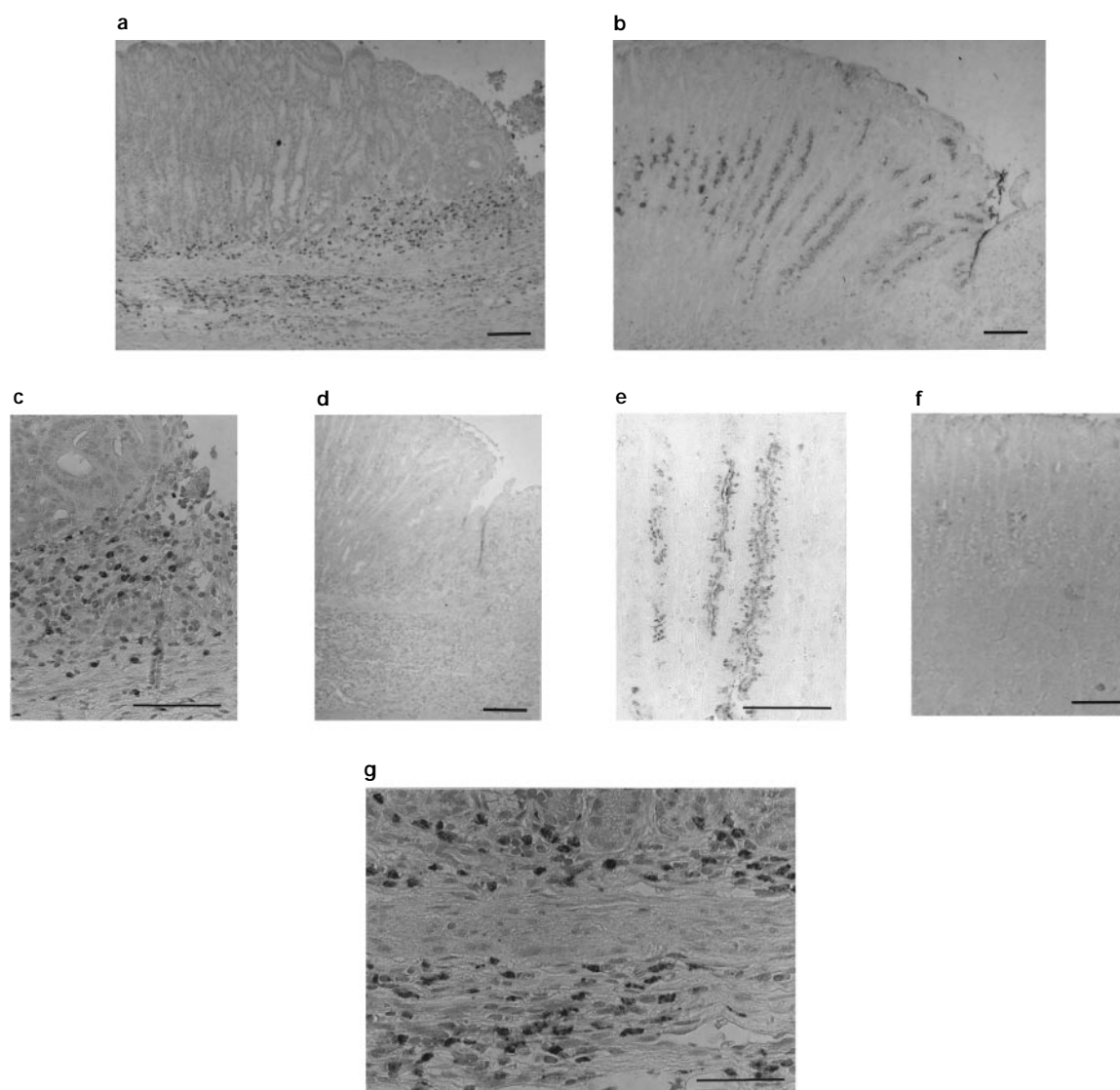


Figure 1 Immunoreactivity of PGHS-1 and PGHS-2 during gastric ulcer healing. Overview of ulcer margin (right ulcer crater, left intact mucosa): immunoreactivity on day 8 for PGHS-2 (a+c) and PGHS-1 (b+e). (g) Immunoreactivity on day 3 for PGHS-2 (lower part of the mucosa, muscularis mucosae and submucosa). Control slides with preabsorbed antibodies for PGHS-2 (d) and PGHS-1 (f). PGHS-2 immunoreactivity was detected in monocytes, macrophages, fibroblasts and endothelial cells which were localized in regions of maximal repair activity: (1) below the regenerative glands of the ulcer margin and scar (a, c, g), (2) in a 1–2 mm wide region of submucosa adjacent to the ulcer crater (g) and (3) in the basal layer of the lamina propria of the mucosa adjacent to the ulcer crater (g). PGHS-2 immunoreactivity was negligible in the normal gastric wall (left side of a). PGHS-1 immunoreactivity was detected both in the neck region of the intact mucosa (left side of b) and in the regenerative glands of the ulcer margin predominantly in the cytoplasm close to the apical membrane (right side of b, e). Bar = 100 μ m.

The mean thickness of the normal oxyntic mucosa in rats without gastric ulcers was $618 \pm 9 \mu$ m. The ulcer size, as assessed by video endoscopy, correlated closely ($r=0.93$) with the ulcer size, as assessed by quantitative histomorphometry. We could not detect any differences between the placebo administered by the s.c. or the i.g. route, and all placebo data were pooled for further analysis.

In the placebo-treated rats in the chronic gastric ulcer healing model, ulcer diameters on days 3, 8 and 15, as assessed by repeated video endoscopy, were 3.8 ± 0.2 mm (100%), 2.2 ± 0.1 mm (58% of initial size), and 0.9 ± 0.1 mm (24% of initial size), respectively. Indomethacin, diclofenac and L-745,337 dose-dependently decreased ulcer healing, resulting in larger gastric ulcers on day 15 (Figures 3 and 4). Compared with placebo treatment, inhibition of gastric acid secretion by omeprazole decreased the ulcer diameter on day 15 and

reversed indomethacin-induced and L-745,337-induced effects on ulcer diameter (Figures 3 and 4).

Indomethacin, diclofenac and L-745,337 dose-dependently decreased the epithelial cell proliferation in the ulcer margin on day 8 (Figure 5a), decreased the microvessel density in the ulcer bed on day 8 (Figure 5b), increased the thickness of the granulation tissue of the ulcer bed on day 15 (Figure 5c) and increased the gap between both edges of the muscularis mucosae on day 15 (Figure 5d).

Intestinal perforation occurred in 1 of 16 rats treated with 0.5 mg (1.4μ mol) kg^{-1} indomethacin, s.c., 2 of 12 rats with 1 mg (3.14μ mol kg^{-1} diclofenac, i.g., 7 of 16 rats with 2.5 mg (7.85μ mol) kg^{-1} diclofenac, i.g., 2 of 12 rats with 2 mg kg^{-1} L-745,337, i.g., and 6 of 16 rats with 5 mg (12.8μ mol) kg^{-1} L-745,337, i.g. (all doses administered twice daily). Intestinal perforation predominantly occurred on days 10–15.

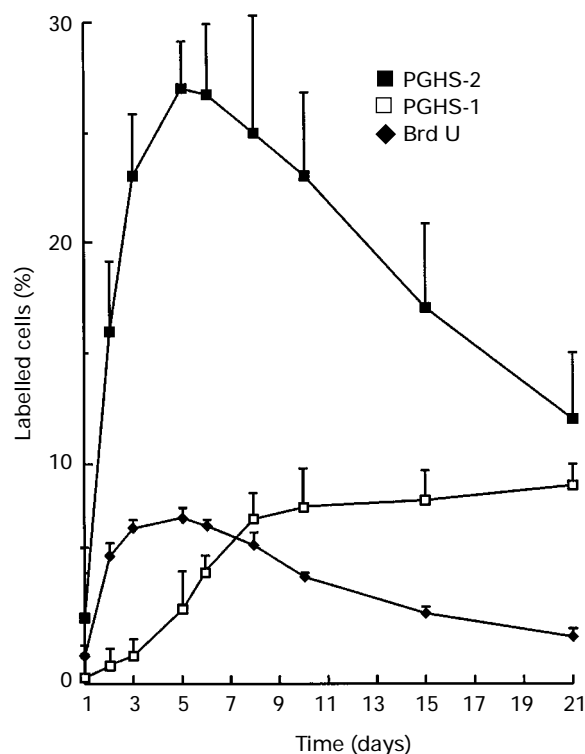


Figure 2 Time-sequence of immunoreactivity for PGHS-2, PGHS-1 and BrdU. Time-sequence of immunoreactivity of PGHS-2 in non-epithelial cells in the connective tissue below the regenerative glands, PGHS-1 in the epithelial cells of the ulcer margin and BrdU in epithelial cells of the ulcer margin. The maximal immunoreactivities for PGHS-2 and BrdU were on day 5.

The plasma gastrin levels in placebo-treated rats were 109 ± 11 and 95 ± 11 pmol l⁻¹ on days 1 and 15, respectively. In comparison, the plasma gastrin levels were significantly ($P < 0.001$) increased 5 fold in all ($n = 24$) omeprazole-treated rats. Indomethacin, diclofenac and L-745,337 monotherapy did not affect plasma gastrin levels.

The ulcer healing rate from days 8–15 was $4.8 \pm 0.5\%$ ($n = 32$) in placebo-treated rats and was substantially ($P < 0.001$) decreased by indomethacin (2×0.5 (1.4 μ mol) mg mg⁻¹, s.c., $n = 15$), diclofenac (2×2.5 mg (7.85 μ mol) kg⁻¹, i.g., $n = 9$), and L-745,337 (2×5 mg (12.8 μ mol) kg⁻¹, i.g. $n = 10$), to $2.6 \pm 0.4\%$, $1.4 \pm 0.3\%$, and $1.6 \pm 0.3\%$, respectively (maximal inhibition: 4.8% (placebo) - 1.4% (diclofenac) = 3.4%) (Figure 6a).

Acute model for assessing induction of gastro-intestinal ulceration

L-745,337 caused no gastric ulceration (even at 20 mg (51.2 μ mol) kg⁻¹, i.g.). In contrast, indomethacin caused dose-dependent gastric ulceration 5 h after i.g. administration (lesion score: 4 ± 1 at 5 mg (14.0 μ mol) kg⁻¹ and 17 ± 3 at 20 mg (56.0 μ mol) kg⁻¹). Twenty-four hours after dosing, L-745,337 (20 mg (51.2 μ mol) kg⁻¹, i.g.) had not caused any detectable intestinal lesions, whereas indomethacin (20 mg (56.0 μ mol) kg⁻¹, i.g.) caused intestinal ulceration (lesion score: 63 ± 8). L-745,337 (2×5 mg (12.8 μ mol) kg⁻¹, i.g.), administered daily for 4 days, did not cause any detectable intestinal ulceration. However, daily administration of indomethacin (2×5 mg (14.0 μ mol) kg⁻¹, i.g.) caused intestinal ulceration and intestinal perforation in all rats, usually on the second day of treatment.

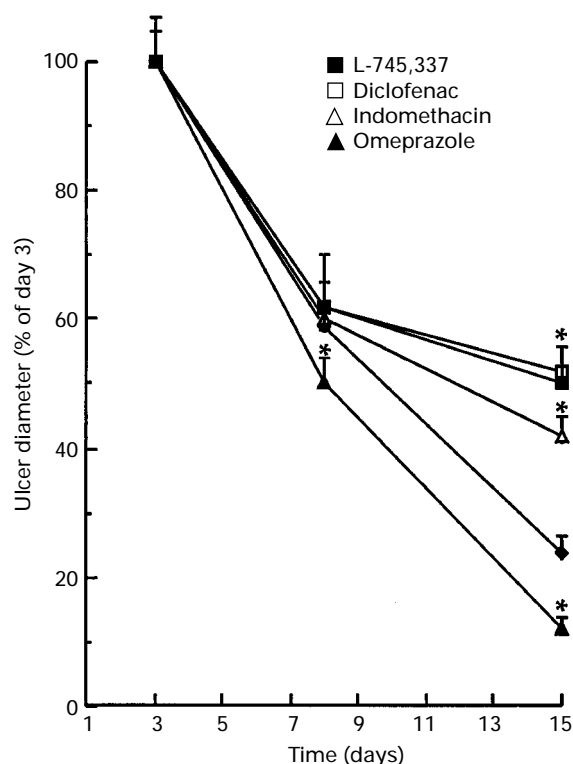


Figure 3 Ulcer diameter – time curve. All inhibitors of prostaglandin endoperoxide synthase (PGHS) decreased gastric ulcer healing. The selective PGHS-2 inhibitor L-745,337 (2×5 mg (12.8 μ mol) kg⁻¹, i.g.) delayed gastric ulcer healing similarly to that of the two non-selective PGHS inhibitors diclofenac (2×2.5 mg (7.8 μ mol) kg⁻¹, i.g.) and indomethacin (2×0.5 mg (1.4 μ mol) kg⁻¹, s.c.). Inhibition of gastric acid secretion by omeprazole accelerated gastric ulcer healing. * $P < 0.002$.

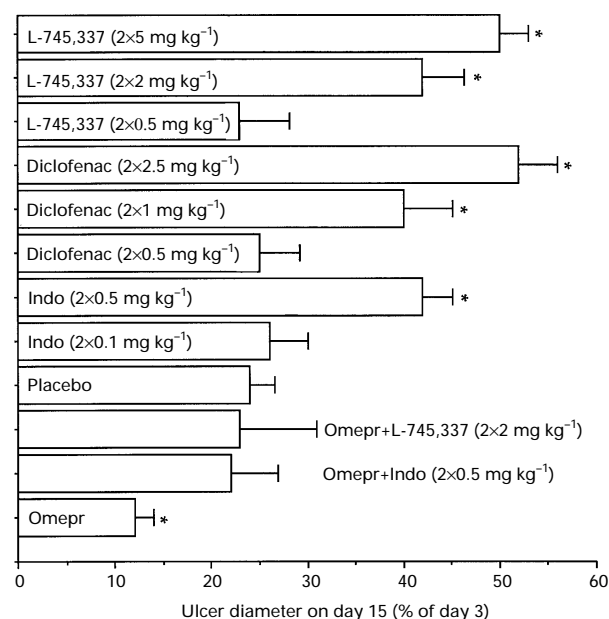


Figure 4 Ulcer diameter on day 15 (as % of day 3). All inhibitors of prostaglandin endoperoxide synthase (PGHS) dose-dependently increased the gastric ulcer diameter on day 15. Compared with placebo treatment, inhibition of gastric acid secretion by omeprazole (Omepr) decreased the ulcer diameter on day 15 and reversed indomethacin (Indo)-induced and L-745,337-induced effects on ulcer diameter compared with placebo results. * $P < 0.002$.

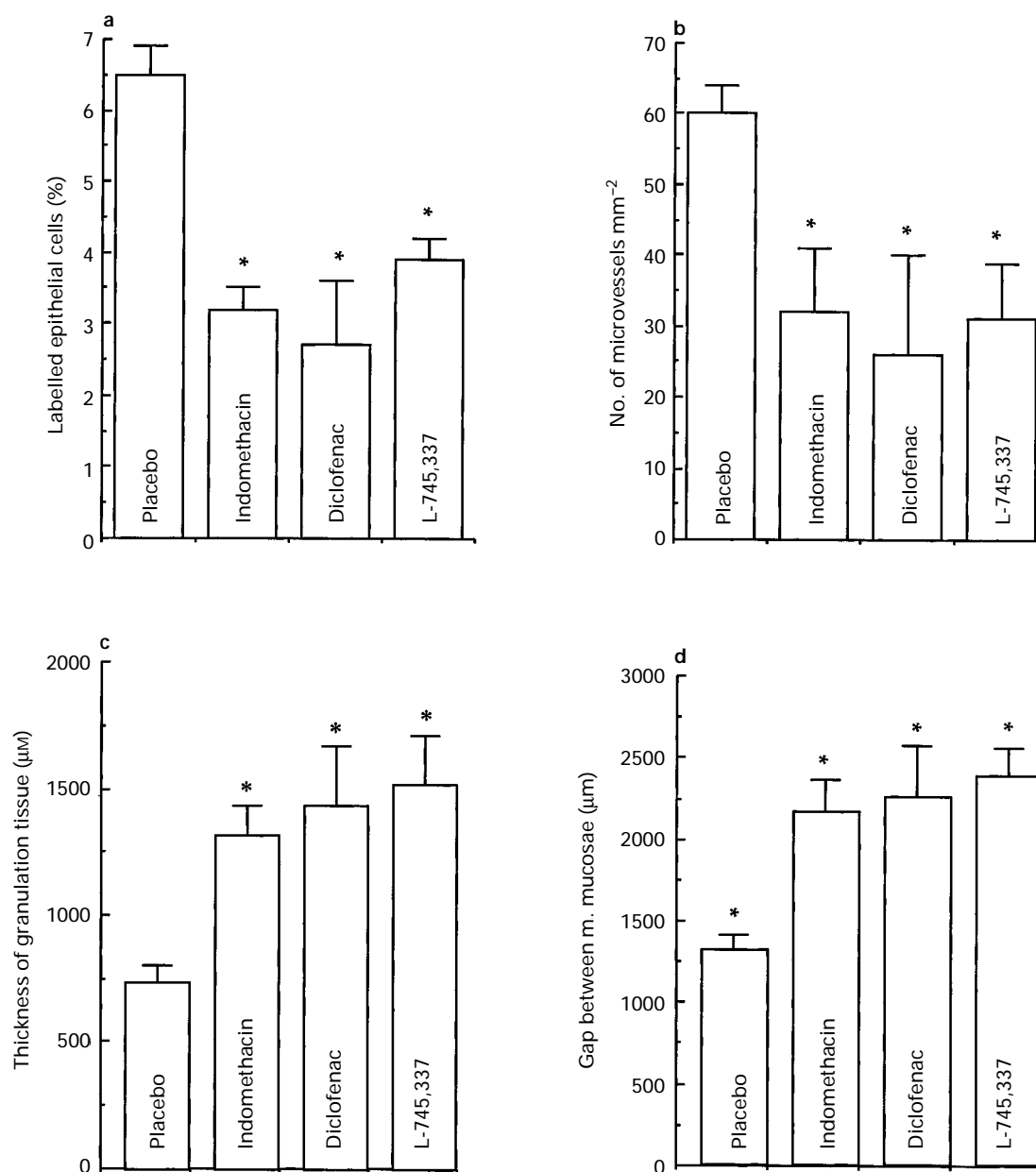


Figure 5 Quantitative histological changes: all inhibitors of prostaglandin endoperoxide synthase significantly changed the following histological healing parameters. (a) Epithelial cell proliferation in the ulcer margin on day 8; (b) microvessel density in the ulcer bed on day 8; (c) thickness of granulation tissue of the ulcer bed on day 15; (d) gap between both edges of the muscularis mucosae on day 15. Doses of indomethacin: $2 \times 0.5 \text{ mg}$ ($1.4 \text{ } \mu\text{mol}$) kg^{-1} , diclofenac $2 \times 2.5 \text{ mg}$ ($7.8 \text{ } \mu\text{mol}$) kg^{-1} and L-745,337: 2×5 ($12.8 \text{ } \mu\text{mol}$) mg kg^{-1} . * $P < 0.01$.

Prostanoid synthesis in chronic and acute gastrointestinal models

In placebo-treated rats in the chronic gastric ulcer healing study, the synthesizing capacity of the intact oxyntic mucosa for 6-keto-PGF_{1α} and PGE₂ was 911 ± 106 and $577 \pm 71 \text{ pg mg}^{-1} 10 \text{ min}^{-1}$, respectively. The synthesizing capacity in the terminal ileum for 6-keto-PGF_{1α} and PGE₂ was 787 ± 67 and $1224 \pm 91 \text{ pg mg}^{-1} 10 \text{ min}^{-1}$, respectively. TXB₂ concentration in the serum was 90 ng ml^{-1} . Both indomethacin ($2 \times 0.5 \text{ mg}$ ($1.4 \text{ } \mu\text{mol}$) kg^{-1} , s.c.) and diclofenac ($2 \times 2.5 \text{ mg}$ ($7.8 \text{ } \mu\text{mol}$) kg^{-1} , i.g.) decreased ($P < 0.01$) gastric 6-keto-PGF_{1α} synthesis by 42% and 88%, respectively, and decreased ($P < 0.05$) 6-keto-PGF_{1α} synthesis in the terminal ileum by 38% and 65%, respectively. Furthermore, indo-

methacin and diclofenac decreased ($P < 0.01$) platelet TXB₂ synthesis by 76% and 67%, respectively. L-745,337, at all tested doses, did not significantly affect prostanoid synthesis in the stomach, terminal ileum or platelets.

In acute studies, 5 h after a single dose of 5 mg ($14.0 \text{ } \mu\text{mol}$) or 20 mg ($56.0 \text{ } \mu\text{mol}$) kg^{-1} indomethacin, i.g., PGE₂ synthesis in the stomach was ($P < 0.01$) reduced by 71% and 81%, respectively. Five hours after a single dose of 5 mg ($14.0 \text{ } \mu\text{mol}$) or 20 mg ($56.0 \text{ } \mu\text{mol}$) kg^{-1} indomethacin, i.g., PGE₂ synthesis in the ileum was ($P < 0.01$) reduced by 61% and 68%, respectively. In contrast, L-745,337 did not significantly affect prostaglandin (6-keto-PGF_{1α} and PGE₂) synthesis in the stomach or the ileum. After daily dosing of L-745,337 ($2 \times 5 \text{ mg}$ ($12.8 \text{ } \mu\text{mol}$) kg^{-1}) for 4 days, no ulcers were detected in the stomach or intestine. 6-Keto-PGF_{1α} and PGE₂ synthesis,

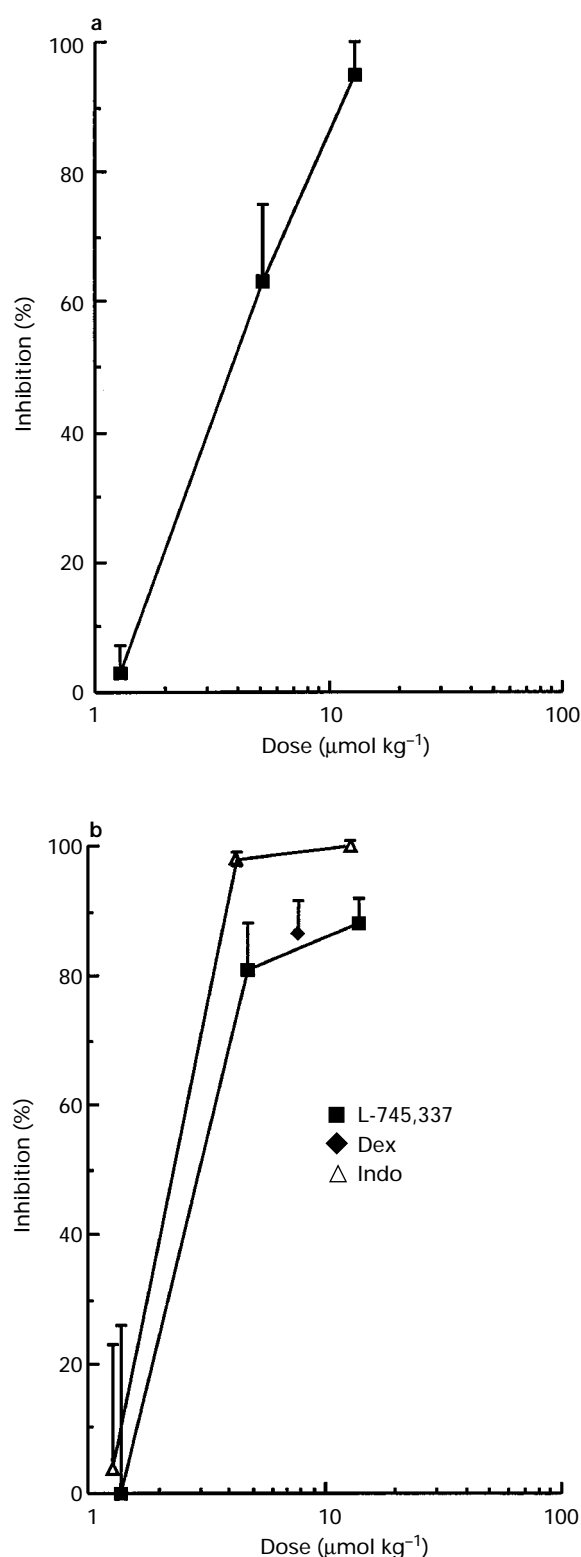


Figure 6 Effects of different doses of L-745,337 on gastric ulcer healing and inhibition of prostaglandin synthesis in the carrageenin-induced inflammation model. (a) Dose-response curve for inhibition of gastric ulcer healing rate from days 8–15 by L-745,337 which was administered twice daily i.g. (ID_{50} : 1.7 mg ($4.3 \mu\text{mol}$) kg^{-1}). (b) Dose-response curves for inhibition of PGE₂ synthesis in inflammatory exudates in the carrageenin sponge rat model. Indomethacin (5 mg ($14 \mu\text{mol}$) kg^{-1} , s.c.) completely inhibited prostaglandin synthesis. L-745,337 (5 mg ($12.8 \mu\text{mol}$) kg^{-1} , i.g.) and dexamethasone (3 mg ($7.7 \mu\text{mol}$) kg^{-1} , i.g.) inhibited prostaglandin synthesis by 88% and 86%, respectively. ID_{50} values were 1.1 ($3.1 \mu\text{mol}$) mg kg^{-1} and 1.3 ($3.3 \mu\text{mol}$) mg kg^{-1} for indomethacin and L-745,337, respectively.

assessed 1 hour after dosing, were not significantly influenced by the L-745,337 treatment.

Acute model for assessing the anti-inflammatory action of NSAIDs

In placebo-treated rats, PGE₂ concentration in the exudate was $3.4 \pm 0.5 \text{ ng ml}^{-1}$. Indomethacin and L-745,337 dose-dependently inhibited PGE₂ synthesis in the inflammatory exudates of the carrageenin sponge model (Figure 6b). Leucocyte influx into the carrageenin sponge was significantly reduced by indomethacin (5 mg ($14.0 \mu\text{mol}$) g^{-1} , s.c.), L-745,337 (5 mg ($12.8 \mu\text{mol}$) kg^{-1} , i.g.) and dexamethasone (3 mg ($7.7 \mu\text{mol}$) kg^{-1}) by 88%, 60% and 73%, respectively.

Discussion

The gastric ulcer repair process, both in man and in experimental ulcer models, is mediated by the secretion of growth factors, enzymes and extracellular matrix components (Tarnawski & Halter, 1995). This repair process is delayed if gastric prostaglandins are depleted (Schmassmann *et al.*, 1995). In this study, we provide evidence that PGHS-2-derived prostaglandins are important mediators of this repair process.

After experimentally-induced gastric ulceration, epithelial cells as well as monocytes, macrophages, fibroblasts and endothelial cells adjacent to the ulcer crater constitute regions of maximal repair activity. We strongly detected PGHS-2 immunoreactivity in monocytes, macrophages, fibroblasts and endothelial cells in regions of maximal repair activity below and between the regenerative glands. This cellular localization is in agreement with results performed in other inflammatory or repair models (Fu *et al.*, 1990; Lee *et al.*, 1992; Reddy & Herschman, 1994; Hull *et al.*, 1996; Barry *et al.*, 1997). In contrast, PGHS-2 immunoreactivity was negligible in the normal gastric wall (Kargman *et al.*, 1996; Ferraz *et al.*, 1997).

The change in immunoreactivity of PGHS-2 over time was comparable to results obtained in other models (Vane *et al.*, 1994; Mizuno *et al.*, 1997). It revealed a close association between the maximal PGHS-2 expression in regions of maximal repair activity and maximal epithelial cell proliferation in regenerative glands. In contrast, after gastric ulceration PGHS-1 immunoreactivity disappeared from the mucosa adjacent to the ulcer crater, but reappeared in regenerative epithelial cells from day 5 onwards.

It is important to emphasize that PGHS-1 and PGHS-2 are located at different sites and that their maximal expressions follow a different time-sequence. PGHS-1 has been located predominantly in the apical cytoplasm of both in mucous neck cells (Iseki, 1995) and regenerative epithelial cells, which supports the concept that PGHS-1-derived prostaglandins are predominantly responsible for maintaining the integrity of the gastric mucosa. In contrast, PGHS-2 has been detected in the cytoplasm of different cell types located in regions of maximal repair activity. Since prostaglandins act over small distances, depletion of PGHS-2-derived prostaglandins in these regions may delay healing, despite the normal prostaglandin levels in the intact mucosa and regenerative glands.

Our results indicated that the PGHS-2 enzyme may play an important role in gastric ulcer healing and repair. We compared the effects of the selective PGHS-2 inhibitor L-745,337, with those of the nonselective PGHS inhibitors indomethacin and diclofenac. Daily administration of L-745,337, indomethacin and diclofenac for 8 and 15 days caused dose-dependent, significant impairment of gastric ulcer

healing, decrease of epithelial cell proliferation in the ulcer margin, decrease of angiogenesis in the ulcer bed and interference with maturation of granulation tissue in the ulcer bed (Levi *et al.*, 1990; Folkman *et al.*, 1991; Hirose *et al.*, 1991; Schmassmann *et al.*, 1995). Quantitative and qualitative histological analysis of gastric ulcers did not, in fact, detect any differences between rats treated with L-745,337, indomethacin or diclofenac. The dose of L-745,337 used in the present experiment had no effect on the basal prostaglandin levels in the intact gastric mucosa or in the mucosal ulcer margin. Thus, the delayed healing of gastric ulcers may have been exclusively caused by the inhibition of synthesis of PGHS-2 derived prostaglandins by L-745,337.

The exact mechanisms by which NSAIDs interfere with healing is not entirely clear. However, at least some growth-factor mediated repair processes seem to be dependent on prostaglandins. Hepatocyte growth factor (HGF) which is secreted by gastric fibroblasts, improves epithelial cell proliferation in the ulcer margin and has been shown to improve epithelial cell migration and gland lumen formation (Schmassmann *et al.*, 1997). It has also been found that prostaglandins strongly induce the secretion of HGF from human cultured gastric fibroblasts. Furthermore, HGF mRNA is down-regulated at the edges of NSAIDs-induced human gastric ulcers where prostaglandins are depleted (Takahashi *et al.*, 1996).

Angiogenesis and maturation of the granulation tissue were profoundly impaired in rats treated with L-745,337, indomethacin or diclofenac. PGHS-2 immunoreactivity in endothelial cells in the granulation tissue of the ulcer bed has been detected in our study as well as in microvessels of human gastric ulcers (Hull *et al.*, 1996). Furthermore, PGHS-2 immunoreactivity has been detected in cultured human gastric endothelial cells during angiogenesis (Hull *et al.*, 1996). Angiogenesis and maturation of the granulation tissue in the ulcer bed are crucial steps in the repair process and are correlated with the NSAID-induced healing delay (Folkman *et al.*, 1991; Schmassmann *et al.*, 1995).

Although cryoinjury-induced ulceration of the stomach in the rat is a model for gastric ulcers in man, the development of gastric ulcers in the animal model is not equivalent to that in man. The most plausible hypothesis of NSAID-induced gastric ulcerations in man is that defects in prostaglandin synthesis in and action on the gastric mucosa weaken the mucosal resistance or impair mucosal repair, leading to the development of chronic ulcers (Wright *et al.*, 1982). However, regardless of the cause of ulceration, once an ulcer develops it undergoes comparable biological and morphological changes in different species (Tarnawski & Halter, 1995).

Prostaglandin levels in the ulcerated stomach seem to be greater than those in the intact mouse stomach (Mizuno *et al.*, 1997). Our immunohistochemical results support the concept that in the ulcerated stomach both PGHS-1- and PGHS-2-derived prostaglandins contribute to the total synthesis of prostaglandins (Mizuno *et al.*, 1997). If the investigated tissue contains both regenerative glands and connective tissue, expressing both PGHS-1 and PGHS-2, selective PGHS-2 inhibitors decrease the increased PGHS activity to normal values (Mizuno *et al.*, 1997).

Acute intragastric administration of indomethacin caused dose-dependent gastric and intestinal ulceration (Beck *et al.*, 1990). Furthermore, indomethacin and diclofenac significantly decreased the synthesis of 6-keto-PGF_{1 α} and PGE₂ in tissue fragments from the stomach and terminal ileum, and decreased platelet thromboxane B₂ synthesis in clotting whole blood. In contrast, L-745,337 (5–20 mg kg⁻¹, i.g.) had no effect on the synthesis of these prostanoids and did not cause acute gastric or intestinal ulceration. These results essentially confirm previous findings (Boyce *et al.*, 1994; Chan *et al.*, 1995).

Administration of indomethacin, diclofenac and L-745,337 for 15 days caused dose-dependent intestinal perforation. The rather high intestinal toxicity of indomethacin is due to its increased enterohepatic circulation (Beck *et al.*, 1990; Schneider *et al.*, 1990). NSAID toxicity in the small bowel is not well understood and may be caused by a PGHS-independent mechanism (Ligumsky *et al.*, 1990), making the PGHS specificity of the NSAID irrelevant in trying to prevent this kind of damage (Bjarnason *et al.*, 1993).

The effects of L-745,337 and indomethacin on prostaglandin synthesis in inflamed tissue demonstrated in our study, concord well with data from previous studies (Isomaki *et al.*, 1984; Chan *et al.*, 1995; Li *et al.*, 1995). L-745,337 inhibited formation of PGHS-2-derived prostaglandins in inflamed tissue in a similar manner to that of dexamethasone, and it did not inhibit formation of PGHS-1-derived prostanoids in the gastrointestinal tract or in platelets. Analysis of the dose-response curves of L-745,337 for inhibition of the ulcer healing rate and prostaglandin synthesis in inflammatory exudates, revealed that the delay of ulcer healing by L-745,337 occurs within a potentially therapeutic dose-range. There is undoubtedly uncertainty when these data are extrapolated to the situation in man. Nevertheless, they give supportive evidence that the safety margin of L-745,337 may be critical for long-term administration in the presence of preexisting gastric lesions.

A direct comparison of the effects of L-745,337, indomethacin and diclofenac *in vivo* is difficult because of the different pharmacological and pharmacokinetic properties of the compounds (Beck *et al.*, 1990). Whether long-term administration of selective inhibitors of PGHS-2 is in fact safer for the gastrointestinal tract than non-selective inhibitors needs further study, and it seems to depend predominantly on the exact role of PGHS-1- and PGHS-2-derived prostaglandins under both physiological and healing conditions.

In summary, PGHS-2 is markedly accumulated after gastric ulceration in monocytes, macrophages, fibroblasts and endothelial cells in regions of maximal repair activity. Selective inhibition of PGHS-2 by L-745,337 causes impairment of ulcer healing in a potentially therapeutic dose range. PGHS-2-derived prostaglandins may have an important role in mediating the repair process during gastric ulcer healing. Further studies are necessary to assess whether selective PGHS-2 inhibitors delay gastric ulcer healing in man at therapeutic doses.

This work was supported by grants from the Swiss National Science Foundation (No. 32-40901.94) and Deutsche Forschungsgemeinschaft (No. Pe215/6-3).

References

BARRY, O.P., PRATICO, D., LAWSON, J.A. & FITZGERALD, G.A. (1997). Transcellular activation of platelets and endothelial cells by bioactive lipids in platelet microparticles. *J. Clin. Invest.*, **99**, 2118–2127.

BECK, W.S., SCHNEIDER, H.T., DIETZEL, K., NUERNBERG, B. & BRUNE, K. (1990). Gastrointestinal ulcerations induced by anti-inflammatory drugs in rats. Physiochemical and biochemical factors involved. *Arch. Toxicol.*, **64**, 210–217.

- BJARNASON, I., HAYLLAR, J., MACPHERSON & RUSSEL, A.S. (1993). Side effects of nonsteroidal anti-inflammatory drugs on the small and large intestine in humans. *Gastroenterology*, **103**, 1832–1847.
- BOYCE, S., CHAN, C.-C., GORDON, R., LI, C.-S., RODGER, I.W., WEBB, J.K., RUPNIAK, N.M. & HILL, R.G. (1994). L-745,337: A selective inhibitor of cyclooxygenase-2 elicits antinociception but not gastric ulceration in rats. *Neuropharmacology*, **33**, 1609–1611.
- CHAN, C.-C., BOYCE, S., BRIDEAU, C., FORD-HUTCHINSON, A.W., GORDON, R., GUAY, D., HILL, R., LI, C.-S., MANCHINI, J., PENNETON, M., PRASIT, P., RASORI, R., REINDEAU, D., ROX, P., TAGARI, P., VICKERS, P., WONG, E. & RODGER, I.W. (1995). Pharmacology of a selective cyclooxygenase-2 inhibitor, L-745,337: A novel nonsteroidal anti-inflammatory agent with an ulcerogenic sparing effect in rat and nonhuman primate stomach. *J. Pharmacol. Exp. Ther.*, **274**, 1531–1537.
- DONNELLY, M.T. & HAWKEY, C.J. (1997). Review article: COX-II inhibitors—a new generation of safer NSAIDs? *Aliment. Pharmacol. Ther.*, **11**, 227–236.
- FERRAZ, J.G., SHARKEY, K.A., REUTER, B.K., ASFAHA, S., TIGLEY, A.W., BROWN, M.L., MCKNIGHT, W. & WALLACE, J.L. (1997). Induction of cyclooxygenase 1 and 2 in the rat stomach during endotoxemia: role in resistance to damage. *Gastroenterology*, **113**, 195–204.
- FOLKMAN, J., SZABO, S., STOVROFF, M., MCNEIL, P., LI, W. & SHING, Y. (1991). Duodenal ulcer: Discovery of a new mechanism and development of angiogenic therapy that accelerates healing. *Ann. Surg.*, **214**, 414–427.
- FU, J.Y., MASFERER, J.L., SEIBERT, K., RAZ, A. & NEEDLEMAN, P. (1990). The induction and expression of prostaglandin H2 synthase (cyclooxygenase) in human monocytes. *J. Biol. Chem.*, **265**, 16737–16740.
- HIROSE, H., TAKEUCHI, K. & OKABE, S. (1991). Effect of indomethacin on gastric mucosal blood flow around acetic induced gastric ulcers in rats. *Gastroenterology*, **100**, 1259–1265.
- HULL, M.A., BROUGH, J.L. & HAWKEY, C.J. (1996). Increased human gastric endothelial cell COX-2 expression during angiogenesis. *Cut*, **39** (Suppl 3), A190.
- ISEKI, S. (1995). Immunocytochemical localization of cyclooxygenase-1 and cyclooxygenase-2 in the rat stomach. *Histochem. J.*, **27**, 323–328.
- ISOMAKI, H., MARTIO, J., KAARELA, K., KAJANDER, A., KOOTA, K., LEHTINEN, K., LUUKKAINEN, R., MARTIO, T., NISSILA, M., NUOTIO, P. & SARNA, S. (1984). Comparison of the analgesic effect of ten nonsteroidal anti-inflammatory drugs. *Br. J. Rheumatol.*, **23**, 61–65.
- KARGMAN, S., CHARLSON, S., CARTWRIGHT, M., FRANK, J., RIENDEAU, D., MANCINI, J., EVANS, J. & O'NEILL, G. (1996). Characterization of prostaglandin G/H synthase 1 and 2 in rat, dog, monkey, and human gastrointestinal tracts. *Gastroenterology*, **111**, 445–454.
- LAMBRECHT, N., BURCHERT, M., RESPONDEK, M., MUELLER, K.M. & PESKAR, B.M. (1993). Role of calcitonin gene-related peptide and nitric oxide in the gastroprotective effect of capsaicin. *Gastroenterology*, **104**, 1371–1380.
- LEE, S.H., SOYOOLA, E., CHANMUGAM, P., HART, S., SUN, W., ZHONG, H., LIOU, S., SIMMONDS, D. & HWANG, D. (1992). Selective expression of mitogen-inducible cyclooxygenase in macrophages stimulated with lipopolysaccharide. *J. Biol. Chem.*, **267**, 25934–25938.
- LEVI, S., GOODLAD, R.A., LEE, C.Y., STAMP, G., WALPORT, M.J., WRIGHT, N.A. & HODGSON, H.J.F. (1990). Inhibitory effect of non-steroidal anti-inflammatory drugs on mucosal cell proliferation associated with gastric ulcer healing. *Lancet*, **336**, 840–843.
- LI, C.-S., BLACK, W.B., CHAN, C.-C., FORD-HUTCHINSON, A.W., GAUTHIER, J.-Y., GORDON, R., GUAY, D., KARGMAN, S., LAU, C.K., MANCINI, J., QUIMET, N., ROY, P., VICKERS, P., WONG, E., YOUNG, R.N., ZAMBONI, R. & PRASIT, P. (1995). Cyclooxygenase-2 inhibitors. Synthesis and pharmacological activities of 5-methanesulfonamido-1-indanone derivatives. *J. Med. Chem.*, **38**, 4879–4905.
- LIGUMSKY, M., SESTIERI, M., KARMEI, F., ZIMMERMAN, J., OKON, E. & RACHMILEWITZ, D. (1990). Rectal administration on nonsteroidal antiinflammatory drugs. Effect on rat gastric ulcerogenicity and prostaglandin E2 synthesis. *Gastroenterology*, **98**, 1245–1249.
- MIZUNO, H., SAKAMOTO, C., WADA, K., UCHIDA, T., NOGUCHI, H., AKAMATSU, T. & KASUGA, M. (1997). Induction of cyclooxygenase 2 in gastric mucosal lesions and its inhibition by the specific antagonist delays healing in mice. *Gastroenterology*, **112**, 387–397.
- OGIHARA, Y. & OKABE, S. (1993). Mechanism by which indomethacin delays gastric ulcer healing in the rat: Inhibited contraction of the ulcer base. *Jpn. J. Pharmacol.*, **61**, 123–131.
- O'NEILL, G.P. & FORD-HUTCHINSON, A.W. (1993). Expression of mRNA for cyclooxygenase-1 and cyclooxygenase-2 in human tissues. *FEBS Lett.*, **350**, 156–160.
- PANARA, M.R., GRECO, A., SANTINI, G., SCIULLI, M.G., ROTONDO, M.T., PADOVANO, R., DI GIAMBERARDINO, M., CIPOLLONE, F., CUCCURULLO, F., PATRONO, C. & PATRIGNANI, P. (1995). Effects of the novel anti-inflammatory compounds, N-(2-(cyclohexyloxy)-4-nitrophenyl) sulphonamide (NS-398) and 5-methanesulphon-amido-6 (2,4-difluorothio-phenyl)-1-indanone (L-745,337), on the cyclo-oxygenase activity of human blood prostaglandin endoperoxide synthases. *Br. J. Pharmacol.*, **116**, 2429–2434.
- PESKAR, B.M., TRAUTMANN, M., NOWAK, P. & PESKAR, B.A. (1991). Release of 15-hydroxy-5,8,11,13-eicosatetraenoic acid and cysteinyl-leukotrienes in carrageenin-induced inflammation: Effect of non-steroidal anti-inflammatory drugs. *Agents Actions*, **33**, 240–245.
- REDDY, S.T. & HERSCHMAN, H.R. (1994). Ligand-induced prostaglandin synthesis requires expression of the TIS10/PGS-2 prostaglandin synthase gene in murine fibroblasts and macrophages. *J. Biol. Chem.*, **269**, 15473–15480.
- REUTER, B.K., ASFAHA, S., BURET, A., SHARKEY, K.A. & WALLACE, J.L. (1996). Exacerbation of inflammation-associated clonic injury in rat through inhibition of cyclooxygenase-2. *J. Clin. Invest.*, **98**, 2076–2085.
- ROBERT, A., NEZAMIS, J.E., LANCASTER, C. & HANCHER, A.J. (1979). Cyto-protection by prostaglandins in rat. Prevention of gastric necrosis produced by alcohol, HCl, hypertonic NaCl, and thermal injury. *Gastroenterology*, **77**, 433–443.
- SACHS, L. (1973). *Angewandte Statistik*. Berlin, Heidelberg, New-York: Springer.
- SCHMASSMANN, A., STETTLER, C., POULSON, R., TARASOVA, N., HIRSCHI, C., FLOGERZI, B., MATSUMOTO, K., NAKAMURA, T. & HALTER, F. (1997). Roles of hepatocyte growth factor and its receptor met during gastric ulcer healing in rats. *Gastroenterology*, (in press).
- SCHMASSMANN, A., TARNAWSKI, A., FLOGERZI, B., GERBER, H., SANNER, M., VARGA, L. & HALTER, F. (1994). Antacids provide better restoration of glandular structure within the ulcer scar than omeprazole. *Gut*, **35**, 896–904.
- SCHMASSMANN, A., TARNAWSKI, A., PESKAR, B.M., VARGA, L., FLOGERZI, B. & HALTER, F. (1995). Influence of acid and angiogenesis on kinetics of gastric ulcer healing in rats: interaction with indomethacin. *Am. J. Physiol.*, **268**, G276–G285.
- SCHNEIDER, H.T., NUERNBERG, B., DIETZEL, K. & BRUNE, K. (1990). Biliary elimination of non-steroidal anti-inflammatory drugs in patients. *Br. J. Clin. Pharmacol.*, **29**, 127–131.
- TAKAHASHI, M., SHINICHI, O., HATA, Y., MIKAMI, Y., AZUMA, N., NAKAMURA, T., TERANO, A. & OMATA, M. (1996). Hepatocyte growth factor as a key to modulate anti-ulcer action of prostaglandins in stomach. *J. Clin. Invest.*, **98**, 2604–2611.
- TARNAWSKI, A. & HALTER, F. (1995). Cellular mechanisms, interactions, and dynamics of gastric ulcer healing. *J. Clin. Gastroenterol.*, **21** (Suppl. 1), S93–S97.
- VANE, J.R. (1971). Inhibition of prostaglandins as a mechanism of action for aspirin-like drugs. *Nature, New Biol.*, **231**, 232–235.
- VANE, J.R. (1994). Towards a better aspirin. *Nature*, **367**, 215–216.
- VANE, J.R., MITCHELL, J.A., APPLETON, I., TOMLINSON, A., BISHOP-BAILEY, D., CROXTALL, J. & WILLOUGHBY, D.A. (1994). Inducible isoforms of cyclooxygenase and nitric-oxide synthase in inflammation. *Proc. Natl. Acad. Sci. U.S.A.*, **91**, 2046–2050.
- WALLACE, J.L. (1997). Nonsteroidal anti-inflammatory drugs and gastroenteropathy: the second hundred years. *Gastroenterology*, **112**, 1000–1016.
- WRIGHT, J.P., YOUNG, G.O., KLAFF, L.J., WEERS, L.A., PRICE, S.K. & MARKS, I.N. (1982). Gastric mucosal prostaglandin E levels in patients with gastric ulcer disease and carcinoma. *Gastroenterology*, **82**, 263–267.
- XIE, W., CHIPMAN, J.G., ROBERTSON, D.L., ERIKSON, R.L. & SIMMONDS, D.L. (1991). Expression of a mitogen-responsive gene encoding prostaglandin synthase is regulated by mRNA splicing. *Proc. Natl. Acad. Sci. U.S.A.*, **88**, 2692–2696.

(Received November 3, 1997
Accepted November 13, 1997)